RATE

300 150 100 75 60 50 43



- Count number of complexes x 6 (standard ECG = 10sec)

RHYTHM

- Locate the P wave (rate, axis, morphology)
- What is the relationship between the P wave and QRS?
- Analyze QRS morphology

AXIS DEVIATION

	Lead I QRS	Lead II/aVF QRS
Normal (-30 to 90°)	+	+
Left	+	-
Right	-	+

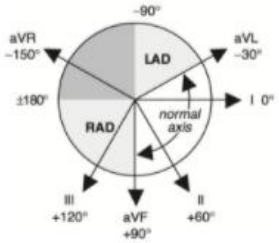

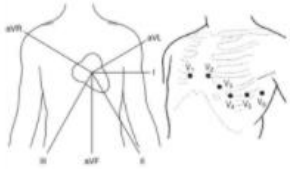

HYPERTROPHY

- LEFT ATRIAL ENLARGEMENT (P mitrale)
  - P wave > 0.12sec and bifid in lead II
- RIGHT ATRIAL ENLARGEMENT (P pulmonale)
  - P wave > 0.25mV in lead II
- LVH
  - R wave in V5 or V6 >25mm
  - S wave in V1 or V2 >25mm
  - Sum of R wave in V5 or V6 + S wave in V1 >35mm
- RVH
  - R wave > S wave in V1

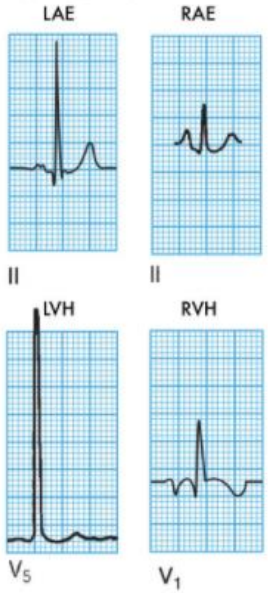

WAVES, INTERVALS, & SEGMENTS

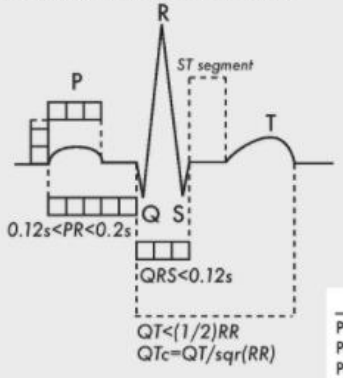

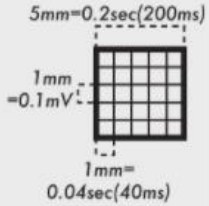

	99%ile QTc
Prepuberty	460ms
Postp Males	470ms
Postp Females	480ms

NORMAL Q WAVES

- Small (septal) q waves normal in leads aVL, I, II, V5, V6
- Can be normal on expiration in lead III

PATHOLOGICAL Q WAVES (PRIOR MI)

- >1-2 small squares deep (or >25% of R wave)
- >1 small square wide (or ≥30ms)
- More likely diagnostic if with inverted T wave

DOMINANT R WAVE

- In lead V1: normal in young children; seen in RVH, RBB, HCM, posterior MI
- In lead aVR: TCA poisoning, dextrocardia, VT

POOR R WAVE PROGRESSION

- Prior anteroseptal MI, cardiomyopathy, LVH, RVH/COPD, LBBB

SHARP J POINT

- ST seg. & T wave well demarcated, not merged as in STE
- J point elevation is normal in young, healthy athletes

DIFFUSE J POINT

- ST slowly curving with only an area J point can be found

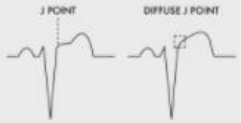

ST SEGMENT ELEVATION

- *(New STE at the J point)*
- In all leads (except V2-V3), significant STE =
  - In two contiguous leads
  - ≥0.1mV
- In leads V2-V3, significant STE =
  - ≥0.15mV in women
  - ≥0.2mV in men ≥40yo
  - ≥0.25mV in men ≤40yo

ST SEGMENT DEPRESSION

- *(New horizontal or down-sloping STD)*
- Significant STD =
  - In two contiguous leads
  - ≥0.05mV
- and/or
  - T-wave inversion ≥0.1mV in two contiguous leads with
  - Prominent R wave or R/S ratio>1

(Known LBBB and pacing make ECG less diagnostic for ACS)

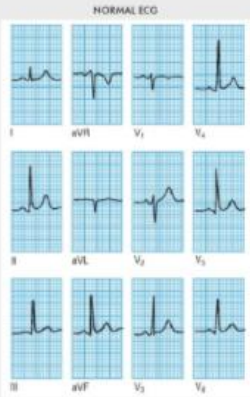

PATTERNS

- Anterior MI (LAD) = V1-V4
- Lateral MI (LCx) = I, aVL, V5-V6
- Anterolateral MI (LAD) = I, aVL, V1-V6
- Inferior MI (RCA, LCx) = II, III, aVF
- Inferolateral MI (RCA, LCx) = I, aVL, V5-V6, II, III, aVF
- Acute posterior MI (RCA or LCx):
  - Dominant R waves in leads V1-V3
  - ST depression in V1-V3
  - Upright, tall T waves

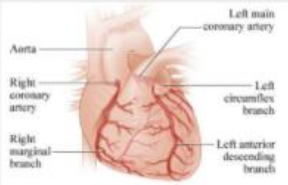

STEMI EVOLUTION

- Hyperacute T waves (tall, peaked, symmetric)
- STE in contiguous leads (concave → convex, merging with T wave)
- Development of Q wave and T wave inversions as ST returns to baseline

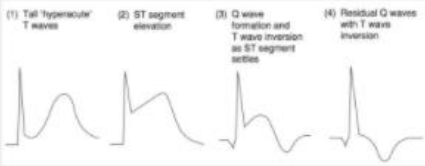

NORMAL INVERTED T WAVES

- Normal in leads aVR, V1
- Can be normal in lead V2 in young pts, lead V3 in black pts, lead III during expiration

INVERTED T WAVES IN ISCHEMIA

- ≥0.1mV in two contiguous leads

TALL T WAVES

- <1/2 preceding QRS

LVH → LV STRAIN PATTERN → TWI in leads I, aVL, V5-6

RVH → RV STRAIN PATTERN → TWI in leads II, III, aVF

BBB

	Normal	
V1: "M" V6: "W"	RBBB	
V1: "W" V6: "M"	LBBB	

www.henrydelrosario.com

SOURCES: ECG tutorials on UpToDate (Basic principles of ECG analysis, Myocardial ischemia and infarction), *Making Sense of the ECG* by Houghton, *Pocket Medicine* by Sabatine; *Third Universal Definition of Myocardial Infarction* by Thygesen et al; lifeinthefastlane.com; compiled by Henry Del Rosario MD; last update 5/2018

Which Leads Look Where?

I (Circ)	aVR	V_1 (LAD)	V_4 (LAD)
II (RCA)	aVL (Circ)	V_2 (LAD)	V_5 (Circ)
III (RCA)	aVF (RCA)	V_3 (LAD)	V_6 (Circ)

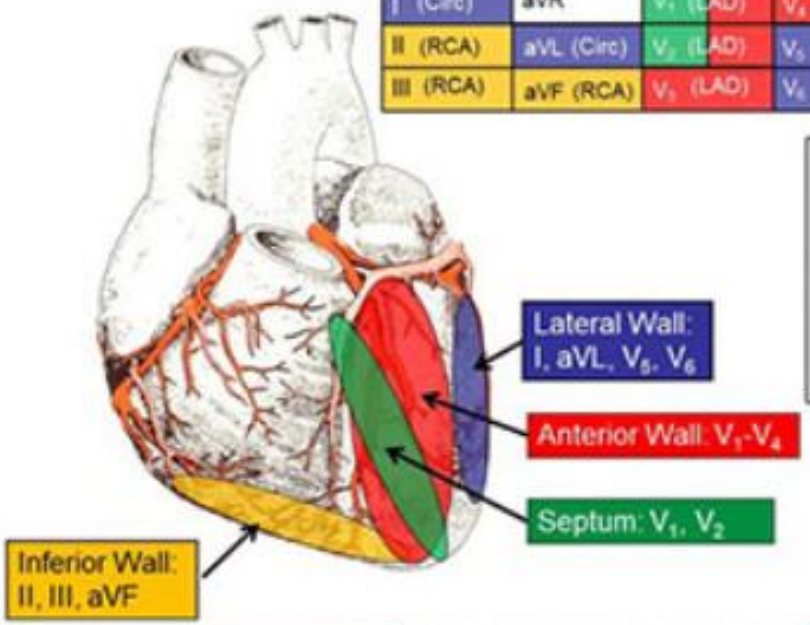
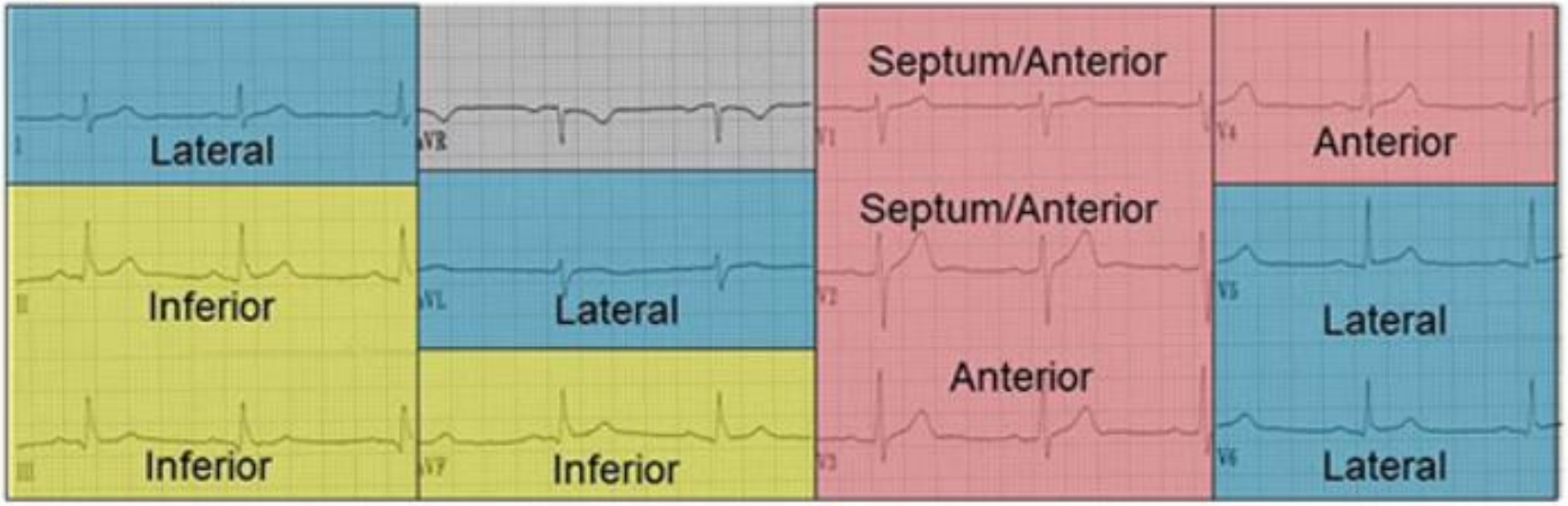
Inferior wall: II, III, aVF
Septum: V1, V2
Anterior wall: V3, V4
Lateral wall: I, aVL (high lateral); V5, V6 (low lateral)
Anterior wall and septum often infarct together because both supplied by LAD, so anteroseptal MI shows in V1-V4